

Erythema Nodosum Leprosum and Orbital Involvement¹

Upreet Dhaliwal, Sandeep Mohanty, and Sambit N. Bhattacharya²

ABSTRACT

This is the first report of ENL involving the orbit in a lepromatous patient with recurrent ENL, receiving MDT. Severe injury to the eye ensued, in spite of continued ENL and appropriate treatment of the reaction.

RÉSUMÉ

Il s'agit du premier cas publié d'érythème noueux lépreux (ENL) de l'orbite de l'œil chez un patient lépromateux traité par la poly-chimiothérapie (PCT), avec ENL récidivant. Des lésions sévères de l'œil en ont été la conséquence, malgré le maintien sans interruption de la PCT et un traitement approprié de la réaction immunopathologique.

RESUMEN

Este es el primer reporte sobre la aparición de una reacción tipo ENL en la órbita de un paciente con lepra lepromatosa y reacciones ENL recurrentes bajo tratamiento con poliquimioterapia. El daño severo en el ojo apareció no obstante el tratamiento apropiado de la reacción.

Erythema nodosum leprosum (ENL), or type II reaction, is an immunological reaction seen in patients with lepromatous leprosy (⁹), developing usually within the first yr of treatment though it has been described in untreated patients (¹⁻⁹). It is proposed to occur either as a result of immune complex disposition or enhanced cell mediated immunity, or both (^{4, 9, 13}). Since lepromatous leprosy is a generalized disease, any organ may be involved in the ENL process (⁹). Lesions described included eruptions of tender, red nodules or papules that arise in apparently normal skin; neuritis; painful lymphadenopathy; enlargement of liver and spleen; epididymo-orchitis; arthritis; periosteitis; myositis; glomerulonephritis; peritonitis and oral destruction (^{4, 9, 11}). Eye complications during ENL reactions have been described in the literature and include lagophthalmos, episcleritis, scleritis, uveitis, keratitis, and secondary glaucoma (^{9, 10}).

We describe a patient with lepromatous leprosy (LL) who had recurrent episodes of ENL and presented with orbital involvement during the most recent episode. Orbital involvement in leprosy, or during reactions, has not been described before in the literature.

CASE REPORT

A 39-year-old male first presented to the dermatology department in November 2000 with multiple, uncountable, evanescent and painful skin lesions of seven days duration. The lesions were erythematous and nodular, and present on the face, forearms, hands, and legs. He was febrile, and had thickened and tender ulnar and superficial peroneal nerves of both sides. The greater auricular, radial, median posterior tibial, lateral popliteal, and sural nerves were also thickened, though non-tender. Fine needle aspiration cytology of the skin lesions showed foamy macrophages and neutrophils, supporting the clinical diagnosis of lepromatous leprosy (LL) in type II reaction (ENL). The Bacterial Index was 4+ to 5+. His erythrocyte sedimentation rate was 40 mm in the first hr (Westergren's method; reference range for males being 0-10 mm) and he was HIV negative (ELISA test). All other hematological and biochemical investigations were normal. He was admitted and treated with dapsone 100 mg/day, clofaza-

¹Received for publication on 2 December 2002. Accepted for publication on 3 February 2003.

²U. Dhaliwal, M.S., Department of Ophthalmology; S. Mohanty, M.D., Department of Dermatology; S. N. Bhattacharya, M.D., Department of Dermatology, University College of Medical Sciences and GTB Hospital, Delhi.

Reprint requests to: Dr. Upreet Dhaliwal, Head, KH-6 New Kavi Nagar, Ghaziabad, 201002, UP, India. Telephone: 91-11-2582971 Ext. 242, FAX: 91-11-2590495, E-mail: upreetdhaliwal@hotmail.com.

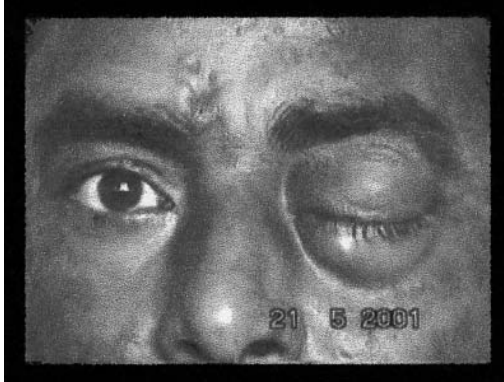

FIG. 1. Old and new skin lesions of ENL on the face, and proptosis of the left eye with complete ptosis.

mine 100 mg tds, rifampin 600 mg/month, and 600 mg/day of oral prednisolone—standard World Health Organization (WHO) regime for MB leprosy with ENL (15). During the next 2 months he did not develop any new lesions of ENL and prednisolone was gradually tapered (15). However, he developed fresh lesions along with orchitis in January 2001, whereupon the dose of prednisolone was again increased to 60 mg/day. After the condition stabilized, the prednisolone was again gradually tapered.

In April 2001, the patient who had been compliant with treatment, developed fever and fresh skin lesions of ENL. He also had orbital pain, loss of vision along with protrusion of and inability to open the left eye. He presented to the ophthalmology department 7 days after the onset of these symptoms. On examination, he has lesions of ENL all over the body. There was proptosis of the left eye with a firm, mildly tender mass palpable in the medial orbit, both su-

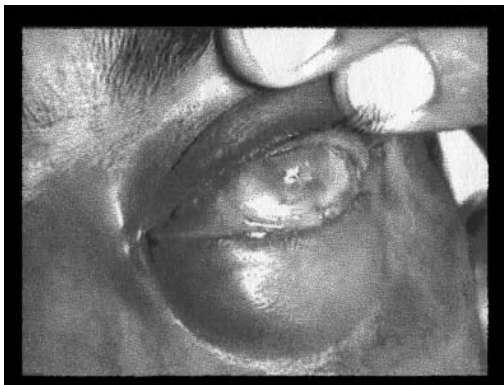


FIG. 2. Scleral melting and corneal edema, suggestive of ocular ischemia, left eye.

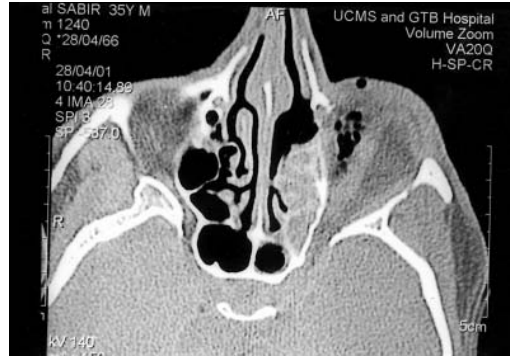


FIG. 3. Axial CT-scan showing marked thickening of the mucosa of the left ethmoidal sinuses.

perior and inferior to the eyeball, in the absence of signs of acute inflammation (Fig. 1). There was no perception of light, complete ptosis, complete ophthalmoplegia, and the absence of corneal sensations suggesting involvement of the IIrd, IIIrd, IVth, Vth, and VIth cranial nerves. There were findings suggestive of ocular ischemia viz. scleral melting, corneal edema, a large corneal epithelial defect, and very low intra-ocular pressure (Fig. 2). Examination of the other eye was normal, as were the testes and joints. Though the erythrocyte sedimentation rate was 120 mm in the first hr (Westergren's method), all other hematological and biochemical investigations, particularly kidney function tests, were normal.

A clinical diagnosis of LL in type II reaction, with left orbital apex syndrome and ocular ischemia was made. The patient continued to receive high doses of systemic steroids, and MB-MDT with 100 mg tds of clofazamine. For the ocular condition, he

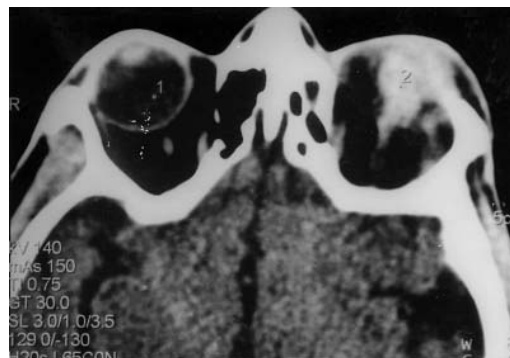


FIG. 4. Axial CT-scan showing air in both orbits and an atrophic, shrunken eyeball on the left side.

was given systemic and local broad spectrum antibiotics and atropine 1% eye ointment. During FNAC of the swelling from the orbit, 2–3 ml of pus was aspirated, which was composed of degenerated cells with neutrophils against a necrotic background. The pus was negative for bacteria or fungus. Nasal smears were negative for AFB, while fine needle aspiration cytology of the skin lesions showed a Bacterial Index of 2+. Computerized tomography scan showed marked thickening of the mucosa of the left maxillary, and ethmoidal sinuses (Fig. 3) and destruction of the medial wall of both orbits, with air in the orbits making further details difficult to delineate (Fig. 4). The left eyeball was proptosed, small, and irregular with shaggy outline suggestive of atrophy (Fig. 4). While the pain and proptosis have markedly reduced over the months of follow up, ophthalmoplegia has persisted and the eye has gone into phthisis bulbi.

DISCUSSION

After passing through the cavernous sinus, the IIIrd, IVth, first branch of the Vth, and the VIth cranial nerves enter the orbit through the superior orbital fissure (7). The optic nerve, along with the ophthalmic artery, enters the orbit through the optic canal. If an inflammatory process involves the orbital apex, it interrupts the nerves at a critical juncture, i.e., the bony canals, and can cause complete ophthalmoplegia, loss of vision, and decreased ocular sensations (the orbital apex syndrome). In addition, inflammatory processes associated with systemic vasculitis may affect the ophthalmic, posterior ciliary, or central retinal artery, thereby causing abrupt onset of blindness, while inflammation of the connective tissue around the blood vessels can produce proptosis (7). Involvement of the ophthalmic artery, particularly, will produce ocular ischemia, while that of the ciliary or central retinal artery causes posterior segment ischemia. In orbital apex syndrome, when there is massive loss of vision, bony destruction, and large elevation of ESR, one must look for a systemic vasculitis (7). While vasculitis due to Wegener's granulomatosis and periarteritis nodosa has been implicated in orbital apex syndrome (7,14), it has not been described as a cause due to ENL in current literature.

The orbital disease may begin in an adjacent sinus, such as the ethmoid, and spread to the orbit, or, less commonly, it may arise as an isolated phenomenon by the fusion of multiple small areas of vasculitis in the orbit (14). Involvement of the paranasal sinuses by the lepromatous process is well recognized (3,5), with radiological changes occurring in the maxillary antrum, ethmoidal, and frontal sinuses (3). Loss of the anterior nasal spine, the alveolar process of maxilla, the perpendicular part of the ethmoid and the vomer have also been described (8). In the patient reported here, there was involvement of the left maxillary and ethmoidal sinuses, with destruction of the medial orbit wall. The disease probably started in the ethmoidal sinus and spread to the orbit.

Because ENL is characterized by an acute vasculitis in which tissue destruction is common, authors (11) have suggested that ENL ulceration, rather than primary lepromatous ulceration, is the major cause of destruction, perforation, or deformation of structures like the palate and uvula. In this patient too, acute vasculitis due to ENL probably caused the severe ocular morbidity described herein.

Features of MB leprosy with polymorphonuclear leukocyte inflammatory cell infiltrate and edema (2,6), cellular infiltrates of blood vessels, and endothelial cell proliferation throughout the dermis (12), and often vasculitis (6) has been found on histopathology of ENL lesions. While we did not biopsy the orbital lesion, FNAC findings of necrosis and neutrophils from orbital pus in a patient with ENL, orbital apex syndrome and ocular ischemia contributed to the diagnosis of vasculitis involving the orbital vessels.

To prevent disabilities due to reactions in leprosy, it is critical to diagnose the reaction early and provide prompt and adequate treatment. The treatment of vasculitis due to ENL is to give high doses of systemic steroids, along with anti-leprosy treatment, in an effort to minimize systemic damage (15). Clofazamine is an effective anti-inflammatory drug in ENL and is especially useful when corticosteroids are to be reduced or withdrawn. The patient reported seven days after the onset of ocular complaints, a time lag usually incompatible with visual recovery. It is possible that the severity of the vasculitis contributed as

much to the ocular morbidity as the delay in reporting to an ophthalmologist.

In summary, we report a patient with MB leprosy and orbital involvement due to vasculitis associated with ENL. Orbital involvement in leprosy, or during reaction, has not been described previously.

REFERENCES

1. BHARGAVA, P., KULDEEP, C. M. and MATHER, N. K. Recurrent erythema nodosum leprosum precipitated by anti-leprosy drugs. *Int. J. Lepr.* **64** (1996) 458–459.
2. BRAKEL, W. H. V., KWAWAS, I. B. and LUCAS, S. B. Reactions in leprosy: an epidemiological study of 368 patients in West Nepal. *Lepr. Rev.* **65** (1994) 190–203.
3. CHAUDHARY, H., THAPPA, D. M., KUMAR, R. H. and ELANGOVAN, S. Bone changes in leprosy patients with disabilities/deformities (a clinico-radiological correlation). *Ind. J. Lepr.* **71(2)** (1999) 203–215.
4. CHOUDHURI, K. The immunology of leprosy; unravelling an enigma. *Int. J. Lepr.* **63(3)** (1995) 430–447.
5. HAUHNAR, C. Z., MANN, S. B. S., SHARMA, V. K., KAUR, S., MEHTA, S. and RADOTRA, B. D. Involvement of maxillary mucosa in lepromatous leprosy. *Int. J. Lepr.* **60(3)** (1992) 390–395.
6. HUSSAIN, R., LUCAS, S. B., KIFAYET, A., JAMIL, S., RAYNES, J., UGAILI, Z., DOSKRELL, H. M., CHIANG, T. J. and MCADAM, K. P. W. J. Clinical and histopathological discrepancies in diagnosis of erythema nodosum leprosum reactions classified by assessment of acute phase proteins SAA and CRP. *Int. J. Lepr.* **63(2)** (1995) 222–230.
7. JAKOBIEC, F. A. and JONES, I. S. Orbital inflammations. In: *Clinical Ophthalmology*, Volume 2. Duane, T. D. and Jaeger, E. A., eds. Philadelphia: Harper and Row, 1986, pp. 1–35.
8. JOB, C. K., KARAT, A. B. A. and KARAT, S. The histopathological appearance of leprosy rhinitis and pathology of septal perforation in leprosy. *J. Laryngol.* **80** (1996) 718–732.
9. NAAFS, B. Current views on reaction in leprosy. *Ind. J. Lepr.* **72** (2000) 97–124.
10. RAJAN, M. A. Longitudinal follow-up of eyes in leprosy. *Ind. J. Lepr.* **70** (1998) 109–114.
11. SCHEEPERS, A. and LEMMER, J. Erythema nodosum leprosum: a possible cause of oral destruction in leprosy. *Int. J. Lepr.* **60(4)** (1992) 641–643.
12. SEHGAL, V. N. and SHARMA, V. Reactions in leprosy—a prospective study of clinical, bacteriological, immunological, and histopathological parameters in thirty-five Indians. *J. Derm.* **15** (1998) 412–419.
13. SENGUPTA, U. Immunopathology of leprosy—current status. *Ind. J. Lepr.* **72** (2000) 381–391.
14. SNEBOLD, N. G. Noninfectious orbital inflammations and vasculitis. In: *Clinical Practice. Principals and Practice of Ophthalmology*, Volume 3. Albert, D. M. and Jakobiec, E. A., eds. Philadelphia: Saunders Co., 1994, pp. 1923–1942.
15. WHO EXPERT COMMITTEE ON LEPROSY. Seventh report. Geneva: World Health Organization, 1998. Tech. Rep. Ser. 874.